



Saccular abdominal aortic aneurysms: A case series

Arunagiri Viruthagiri^{1,*}, Nedounsejane Mandjiny¹, Anand Subramaniyan², G. Pravin Kumar³, V. Senthilvelmurugan⁴

¹Department of Vascular and Endovascular Surgery, Kauvery Hospital, Trichy, Tamilnadu, India

²Department of Cardiology, Kauvery Hospital, Trichy, Tamilnadu, India

³Department of Cardiac Anaesthesiology, Kauvery Hospital, Trichy, Tamilnadu, India

⁴Department of Radiodiagnosis, Kauvery Hospital, Trichy, Tamilnadu, India

*Correspondence: vasanthgiri@gmail.com

Abstract: This case report describes a 44-year-old male presenting with acute abdominal pain due to multiple saccular abdominal aortic aneurysms. The patient had a history of left-leg ischemia and tuberculous lymphadenopathy. Despite previous advice for open repair, the patient deferred treatment. Upon admission, CT angiography revealed multiple saccular aneurysms in the infrarenal aorta and the right common iliac artery. Due to the unsuitable anatomy and suspected inflammatory etiology, endovascular repair was not considered. Open aneurysm repair was performed using a Rifampicin-soaked Dacron graft followed by omentoplasty. A ruptured saccular aneurysm was observed intraoperatively. The patient's postoperative recovery was uneventful, and he was discharged on day 7. Histopathology of the sac and thrombus revealed nonspecific changes. The patient was maintained on oral penicillin post-surgery and was doing well at the weeks follow-up. This case highlights the importance of timely intervention in the management of complex aortic aneurysms and the potential complications associated with delayed treatment.

Keywords: Aortic dilation; vascular pathology; surgical intervention; endovascular repair; open surgical repair

Citation: Arunagiri Viruthagiri, Nedounsejane Mandjiny, Anand Subramaniyan, Pravin Kumar G., Senthilvelmurugan V. Saccular abdominal aortic aneurysms: A case series. *Kauverian Med J*, 2024;2(1):27-31.

Academic Editor: Dr. Venkita S. Suresh

Received: date

Revised: date

Accepted: date

Published: date



Copyright: © 2024 by the authors. Submitted for possible open access publication under the terms and conditions.

1. Introduction

Abdominal aortic aneurysms (AAAs) represent a significant concern in vascular health, with the abdominal aorta being the most frequent location for aneurysm formation within the arterial system [1]. These aneurysms are typically categorized into two distinct morphological types: fusiform and saccular. Fusiform aneurysms are characterized by a symmetrical dilation of the entire circumference of the aorta, while saccular aneurysms present as localized, asymmetrical outpouchings of the vessel wall. While the majority of treatment guidelines and research focus on fusiform aneurysms due to their higher prevalence in Western populations, saccular aneurysms are notably more common in certain regions of the world, particularly in Asian and African countries [2,3].

This disparity in prevalence and the subsequent lack of specific guidelines for saccular AAAs present unique challenges in their management. The rarity of saccular AAAs in Western populations has led to a paucity of large-scale studies and evidence-based recommendations for their treatment. Consequently, clinicians often face difficulties in determining the optimal approach for diagnosing, monitoring, and treating these aneurysms [4]. The management of saccular AAAs is further complicated by their distinct hemodynamic properties and potentially different growth patterns compared to fusiform aneurysms. To address this gap in knowledge and contribute to the existing body of literature, this paper presents and discusses two intriguing cases of saccular abdominal aortic aneurysms, highlighting the complexities involved in their diagnosis, treatment, and fol-

low-up care. These case studies offer valuable insights into the clinical presentation, diagnostic challenges, and treatment considerations specific to saccular AAAs. By examining these cases in detail, we aim to shed light on the unique aspects of saccular AAAs and provide clinicians with practical information to guide their decision-making processes [5].

Through a comprehensive analysis of these cases, we will explore the various imaging modalities employed for accurate diagnosis, discuss the decision-making process for intervention, and evaluate the outcomes of different treatment approaches. Additionally, we will examine the long-term follow-up strategies implemented for these patients, considering the potential for aneurysm recurrence or the development of new aneurysms at other sites [6,7].

By presenting these case studies and reviewing the current literature on saccular AAAs, this paper aims to enhance our understanding of this less common but clinically significant variant of abdominal aortic aneurysms. The insights gained from these cases may contribute to the development of more specific guidelines for the management of saccular AAAs, ultimately improving patient outcomes and reducing the risk of potentially life-threatening complications associated with these aneurysms [8,9].

2. Case Presentation

2.1. Case 1

A 44-year-old male presented with acute onset of excruciating pain abdomen for two days. He presented two years before with an acutely ischemic left leg at Kauvery Hospital, Chennai. On evaluation, he was diagnosed to have multiple saccular abdominal aortic aneurysms with thrombosis of the left popliteal artery. He underwent left popliteal thrombectomy and was advised open repair for aortic aneurysm at a later date. But patient deferred the management of abdominal aortic aneurysm due to personal reasons. He was prescribed Dabigatran (Directly Acting Oral Anticoagulant) and Clopidogrel. He was treated for Tuberculous Lymphadenopathy in 2017 for a year and was declared free from Tuberculosis. He didn't have any other major co morbid illness.

He was admitted and underwent an urgent CT angiogram in view of acute pain abdomen. Imaging showed multiple saccular aneurysms in the infrarenal Aorta with involvement of the right common iliac artery. The largest of saccular aneurysm was at the level of aortic bifurcation (Fig. 1). There was no other acute intra-abdominal pathology other than saccular aneurysms to account for the acute onset of pain abdomen. His white cell count and inflammatory markers were mildly elevated. Endovascular Aortic Aneurysm Repair (EVAR) was not offered in view of the unsuitable anatomy and the inflammatory etiology.

Intraoperatively, he was found to have contained rupture of one of the saccular aneurysms (Fig. 2). He underwent open aneurysm repair with Rifampicin soaked 16 × 8 mm bifurcated Dacron graft and omentoplasty (Fig. 3). Omentoplasty was performed in order to reduce the chance of graft infection and Aorto-enteric fistula. He had an uneventful postoperative recovery.

He was discharged on post-operative day 7. The sac and thrombus sent for histopathology examination showed nonspecific changes. He is being maintained on oral Penicillin as it was an inflammatory aneurysm. At four weeks of follow up, he is doing well.

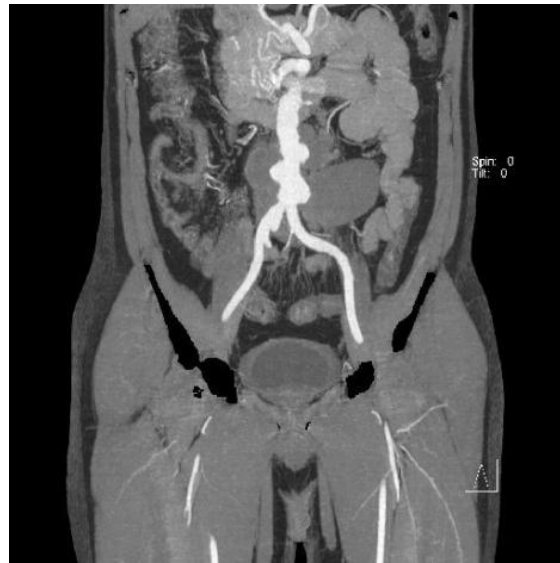

Fig. 1. Saccular aneurysm at the level of aortic bifurcation.

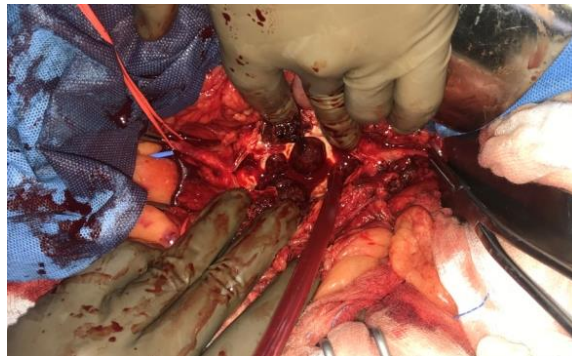


Fig. 2. Multiple saccular aneurysms filled with thrombus at aortic bifurcation.

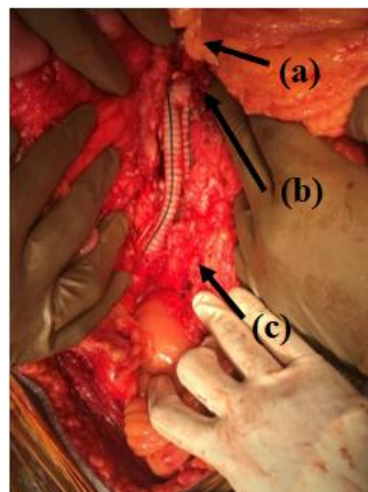


Fig. 3(a). Left Renal Vein, **(b).** Proximal anastomosis at infrarenal aorta, **(c).** Distal anastomosis at right common iliac artery.

2.2. Case 2

A 48-year-old lady presented with upper abdominal pain for one month. The pain was vague with no specific aggravating or relieving factors. She had lost 2 kg of body weight in one month. She had no history of fever, altered bowel habits or malena. She did not have any other co-morbidity. On evaluation, her inflammatory markers (ESR and

CRP) were markedly elevated. CT Angiogram revealed an inflammatory rind (thickening) around the visceral segment of the abdominal aorta and a focal out-pouching at the level of celiac artery (Figs. 4a and 5). There were no clinical or imaging evidence for Takayasu's Aortoarteritis. She was diagnosed to have Non-specific Aortitis with saccular abdominal aortic aneurysm.

She was initiated on Tab. Prednisolone 40 mg once a day and Cap. Doxycycline 100 mg twice a day for a duration of six weeks. Her family members were explained the rationale of starting steroids, the benefits and risks of non-operative management. At six weeks, the inflammatory markers returned to normal. A repeat CT scan showed complete resolution of the periaortic inflammatory activity (Fig. 4b) and reduction in the size of saccular aneurysm by 5 mm.

Subsequently, Prednisolone was tapered gradually to a dose of 10 mg. She is being followed up every month. Her inflammatory markers, blood sugar and blood pressure are being monitored regularly. In her last follow up at six months, she is symptom free. She is being planned for a repeat CT scan.

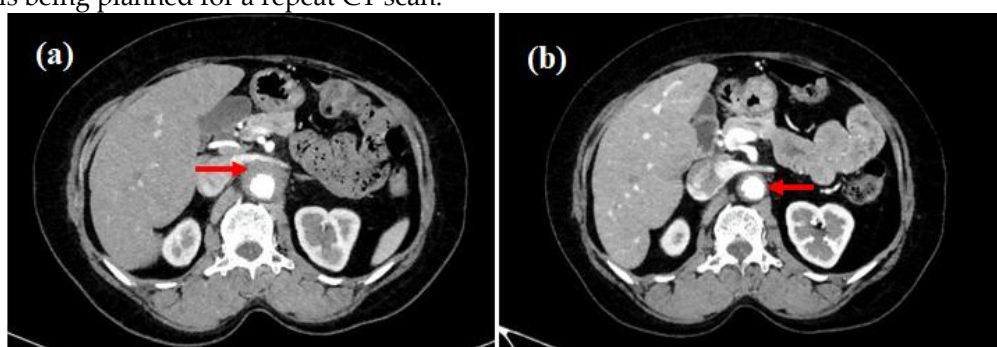


Fig. 4(a). Peri-aortic rind (thickening) prior to treatment, **(b).** Near disappearance of periaortic rind after treatment.

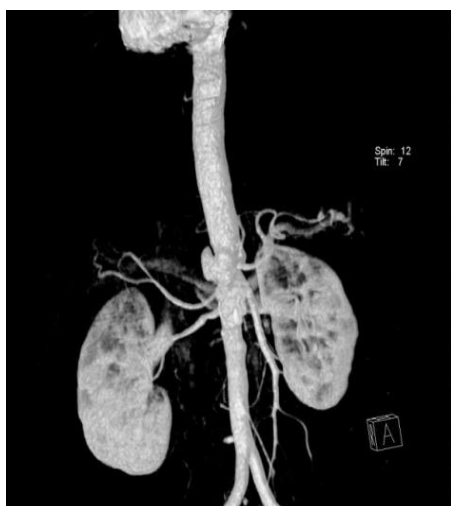


Fig. 5. Saccular abdominal aortic aneurysm seen at the level of celiac artery.

3. Discussion

Index patient 1 presented with acute onset of pain abdomen without any constitutional symptoms. He had been diagnosed with multiple saccular aneurysms in his abdominal aorta, 2 years ago. During this admission, CT angiogram of the abdomen did not reveal any other pathology apart from the saccular aneurysms. The patient was taken up for surgery in view of the symptomatic saccular abdominal aortic aneurysms. The clinical decision to operate on him corroborated with the intra-operative finding of contained rupture from one of the saccular aneurysms.

Index patient 2 presented with vague abdominal pain for a duration of one month. She had constitutional symptoms i.e., fever, weight loss. Her inflammatory markers were markedly elevated and the CT scan revealed inflammatory rind (thickening) around the visceral aorta. The cumulative picture of vague abdominal pain, presence of constitutional symptoms, raised inflammatory markers and imaging evidence of active inflammation around the aorta made us decide towards non-operative management in this patient. At 6 months of follow up she is symptom free and doing well.

4. Conclusions

Saccular aortic aneurysms are a challenging clinical entity. The presence of an aneurysm rings alarm bell for the practicing clinicians. However, the clinical presentation, inflammatory markers and imaging dictate the management strategy which has been amply demonstrated in these two clinical scenarios. The surgical aphorism "When to operate and when not to operate" has been vividly demonstrated in these two patients.

References

1. Karthaus EG, Tong TM, Vahl A, Hamming JF. Saccular abdominal aortic aneurysms: patient characteristics, clinical presentation, treatment, and outcomes in the Netherlands. *Annals of surgery*. 2019 Nov 1;270(5):852-8.
2. Sakalihan N, Michel JB, Katsargyris A, Kuivaniemi H, Defraigne JO, Nchimi A, Powell JT, Yoshimura K, Hultgren R. Abdominal aortic aneurysms. *Nature reviews Disease primers*. 2018 Oct 18;4(1):34.
3. Shang EK, Nathan DP, Boonn WW, Lys-Dobradin IA, Fairman RM, Woo EY, Wang GJ, Jackson BM. A modern experience with saccular aortic aneurysms. *Journal of vascular surgery*. 2013 Jan 1;57(1):84-8.
4. Crawford ES, Beckett WC, Greer MS. Juxtarenal infrarenal abdominal aortic aneurysm. Special diagnostic and therapeutic considerations. *Annals of surgery*. 1986 Jun;203(6):661.
5. Wang LJ, Prabhakar AM, Kwolek CJ. Current status of the treatment of infrarenal abdominal aortic aneurysms. *Cardiovascular diagnosis and therapy*. 2018 Apr;8(Suppl 1):S191.
6. Biasetti J, Gasser TC, Auer M, Hedin U, Labruto F. Hemodynamics of the normal aorta compared to fusiform and saccular abdominal aortic aneurysms with emphasis on a potential thrombus formation mechanism. *Annals of biomedical engineering*. 2010 Feb;38:380-90.
7. Van der Vliet JA, Boll AP. Abdominal aortic aneurysm. *The Lancet*. 1997 Mar 22;349(9055):863-6.
8. Biancari F, Ylönen K, Anttila V, Juvonen J, Ronsi P, Satta J, Juvonen T. Durability of open repair of infrarenal abdominal aortic aneurysm: a 15-year follow-up study. *Journal of vascular surgery*. 2002 Jan 1;35(1):87-93.
9. Schouten O, van Laanen JH, Boersma E, Vidakovic R, Feringa HH, Dunkelgrün M, Bax JJ, Koning J, van Urk H, Poldermans D. Statins are associated with a reduced infrarenal abdominal aortic aneurysm growth. *European journal of vascular and endovascular surgery*. 2006 Jul 1;32(1):21-6.