



Diagnostic Images

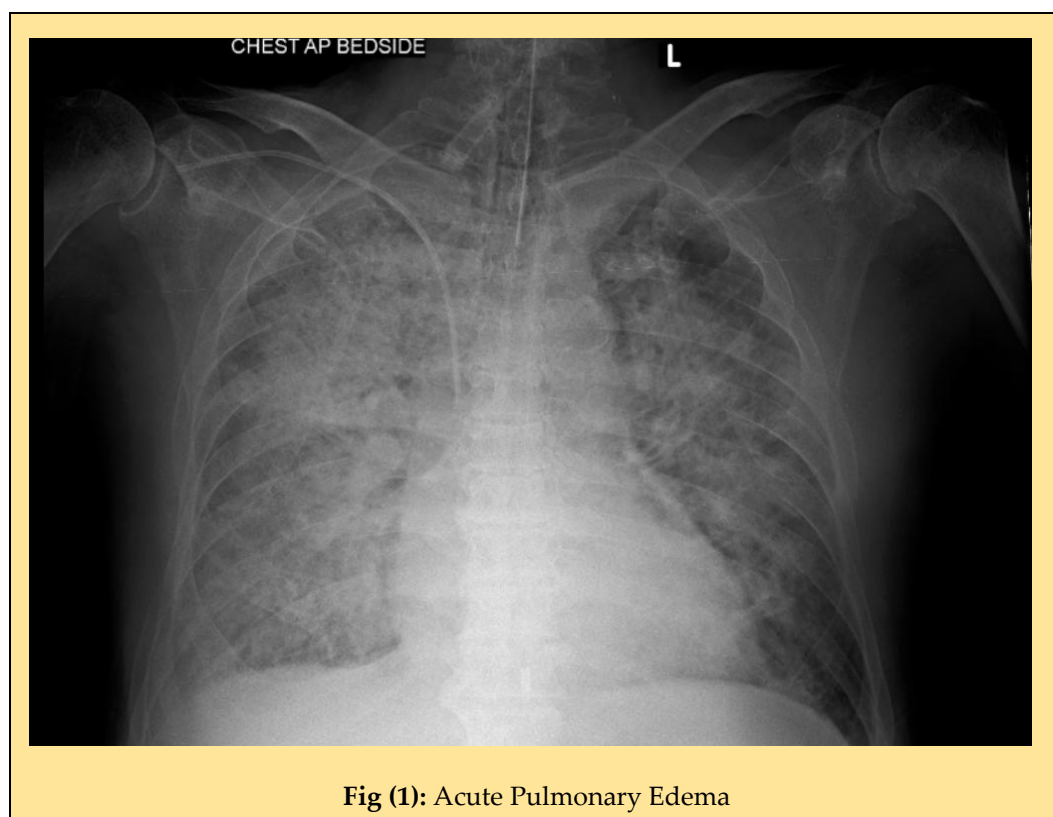
Diagnostic Images: X-ray spotters

Meenakshi Paramasivan *

Department of Radiology, Kauvery Hospital, Tirunelveli, Tamil Nadu

*Correspondence

Clinical Images



Citation: Meenakshi Paramasivan. Diagnostic Images: X-ray spotters. Kauverian Med J. 2025;3(2):36-39.

Academic Editor: Dr. Venkita S. Suresh

ISSN: 2584-1572 (Online)



Copyright: © 2025 by the authors. Submitted for possible open access publication under the terms and conditions.

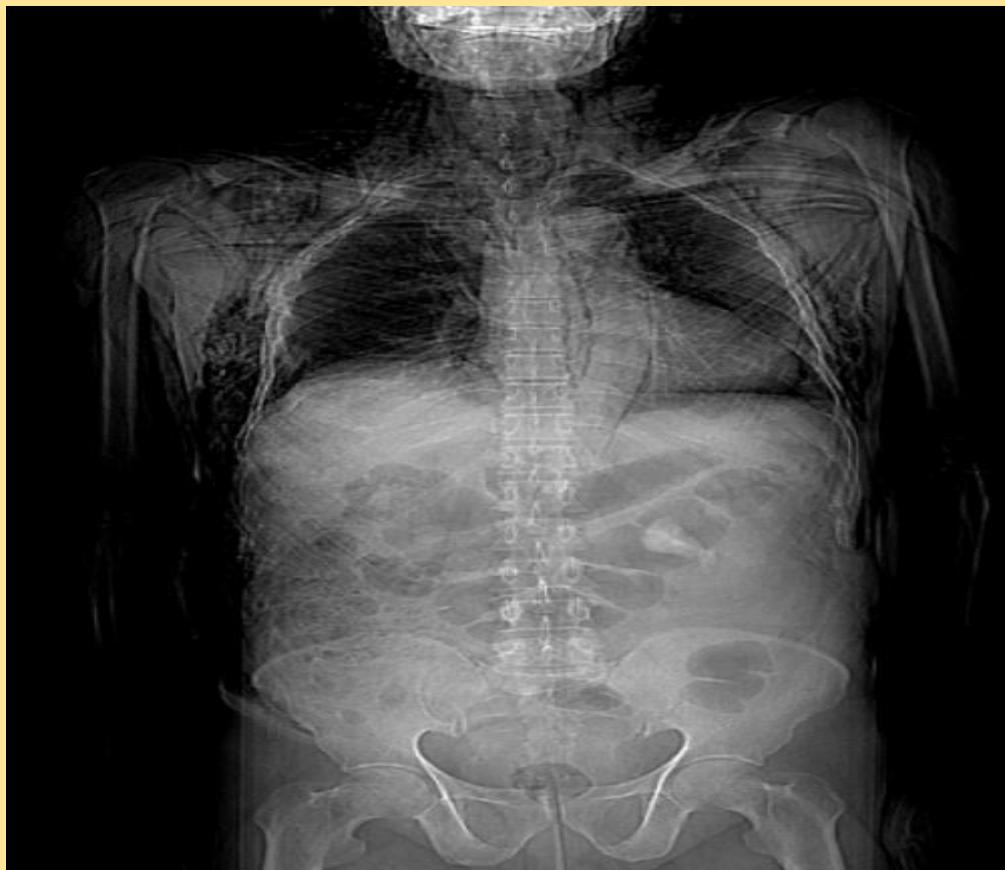

Fig (2): Extensive surgical emphysema along neck chest and abdomen due to rib fractures

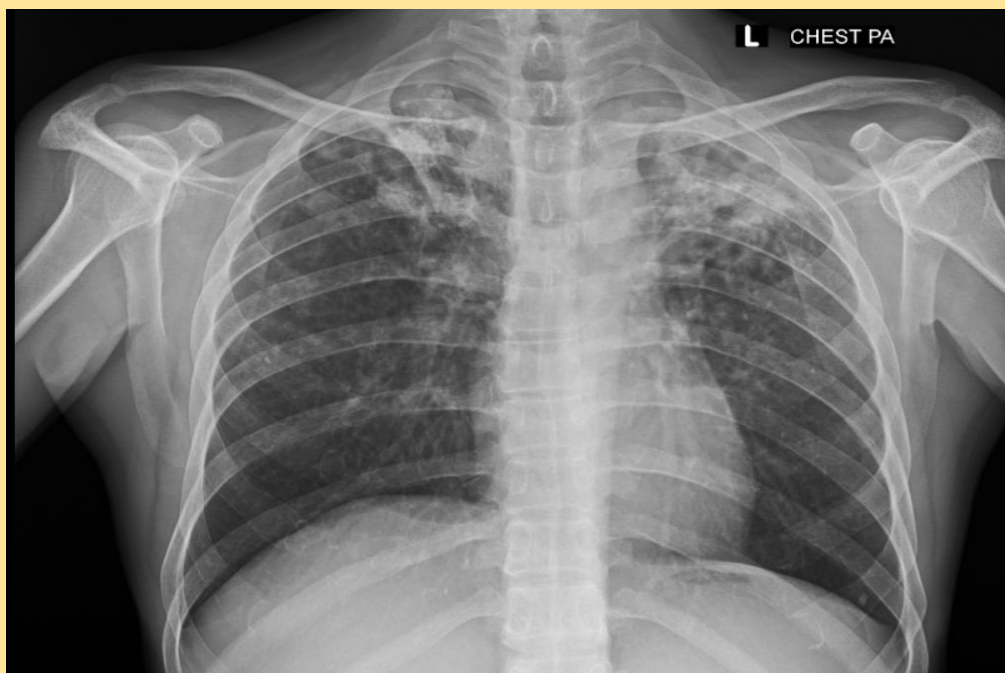


Fig (3): Bilateral upper lobe cavities - Active Koch's

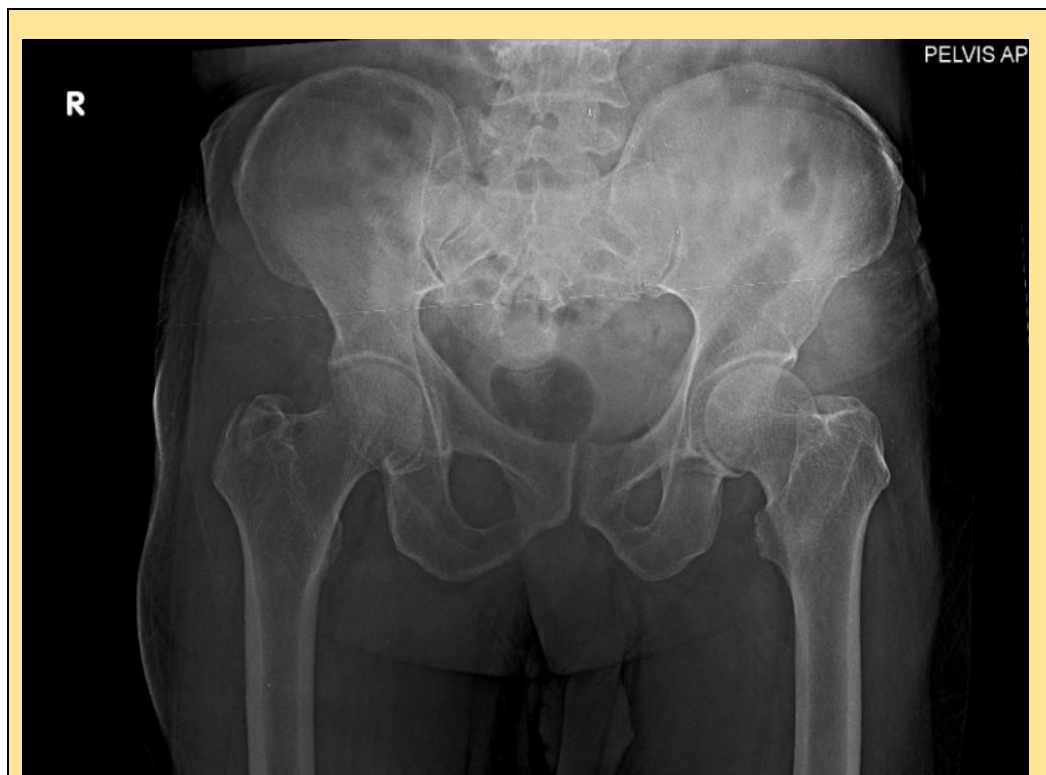

Fig (4): Fracture greater trochanter of right femur

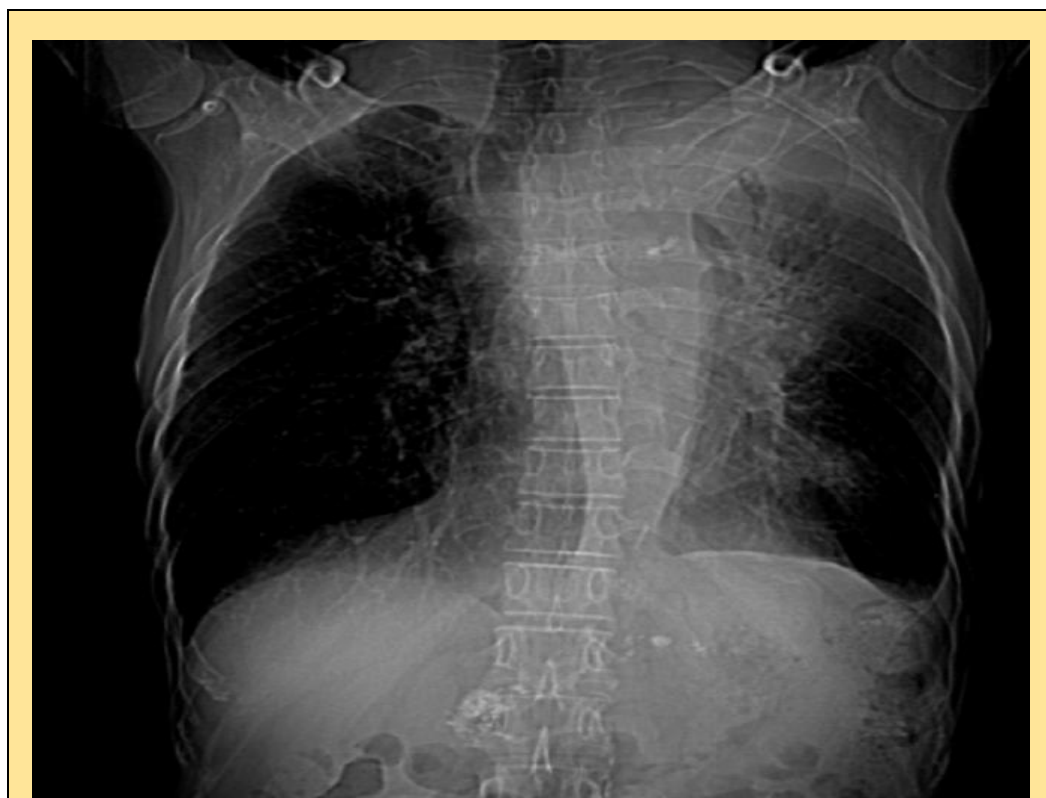


Fig (5): Abdomen shows chronic calcific pancreatitis

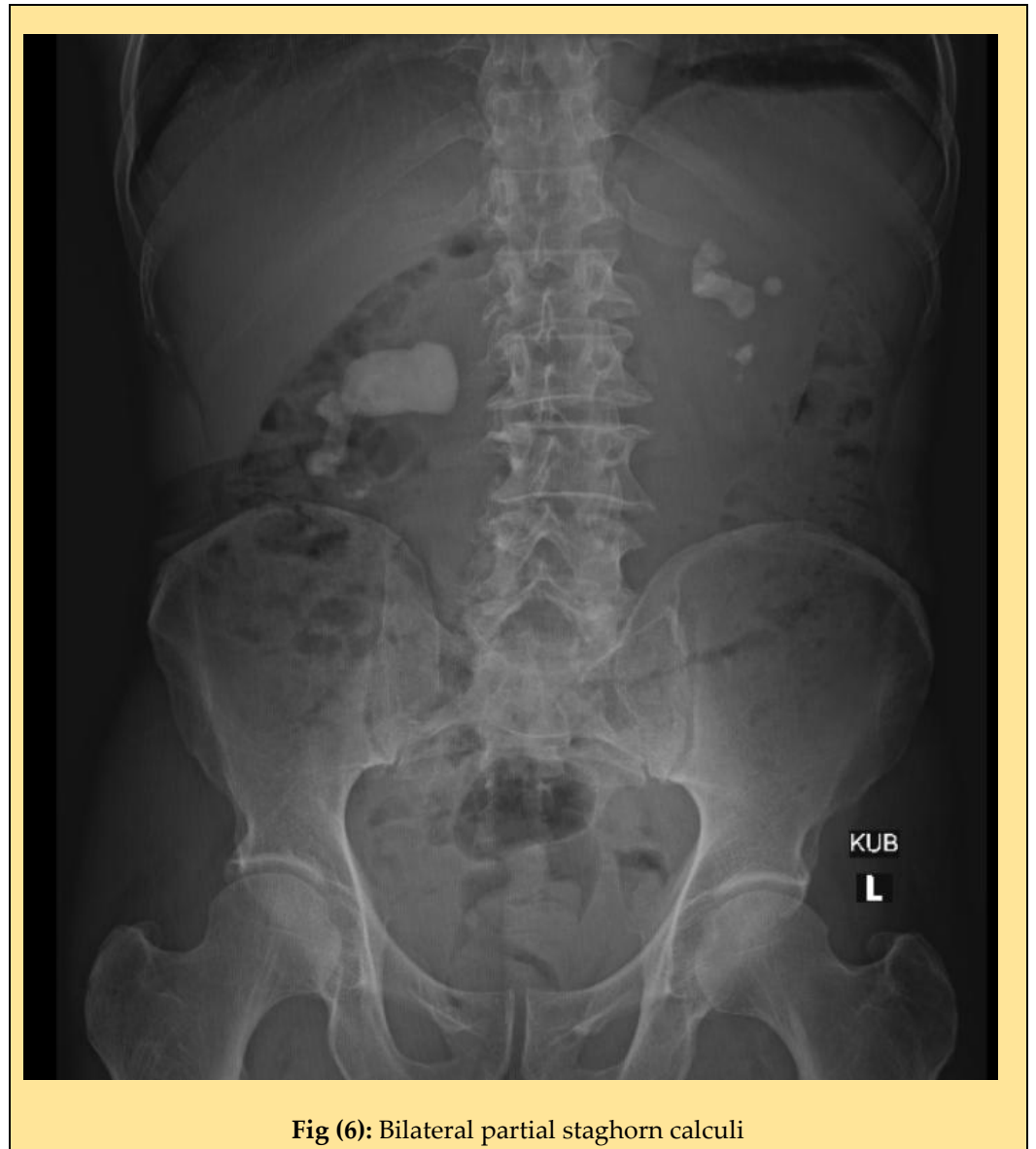

Fig (6): Bilateral partial staghorn calculi