



Case Report

Uterine artery embolization (UAE)

S. Zakir Hussain*

Interventional Radiology, Maa Kauvery, Kauvery Hospital, Trichy, Tamil Nadu

*Correspondence

Abstract

Background: Uterine Artery Embolization (UAE) has emerged as a highly effective, minimally invasive alternative to traditional surgery for various gynecological and obstetric conditions. This report presents two distinct cases that highlight the clinical utility and versatility of UAE

Key words: Uterine Artery Embolization (UAE); Benign Prostatic Hyperplasia; Multiple Myeloma

1.1. Case 1

A successful uterine artery embolization (UAE) was performed yesterday in a 29/F, post-MTP (15 days prior), who developed uterine AVM; initially managed medically, but after 1 week she presented with profuse PV bleeding, so we proceeded with UAE. The procedure was successful with complete embolization and immediate control of bleeding; she remained hemodynamically stable, showed good clinical recovery, and was discharged within 24 hours. This case highlights timely intervention, minimally invasive management avoiding surgery, and excellent multidisciplinary coordination.

1.2. Case 2

A successful prostate artery embolization (PAE) was performed in a 78-year-old male who presented with hematuria, reduced urine output, and fever, a known case of Benign Prostatic Hyperplasia with comorbid Multiple Myeloma (post-chemotherapy) and Chronic Liver Disease with portal hypertension; in view of persistent hematuria and high surgical risk, PAE was performed with effective embolization and prompt control of bleeding, following which the patient remained hemodynamically stable with resolution of hematuria and improved urine output, and demonstrated significant prostate volume reduction from 124 cc pre-procedure to 58 cc on follow-up, highlighting the effectiveness of this minimally invasive approach in high-risk patients.

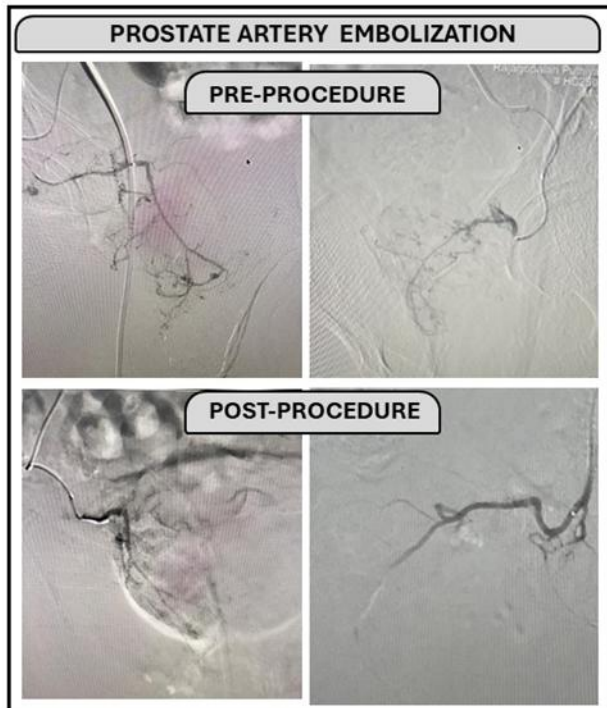
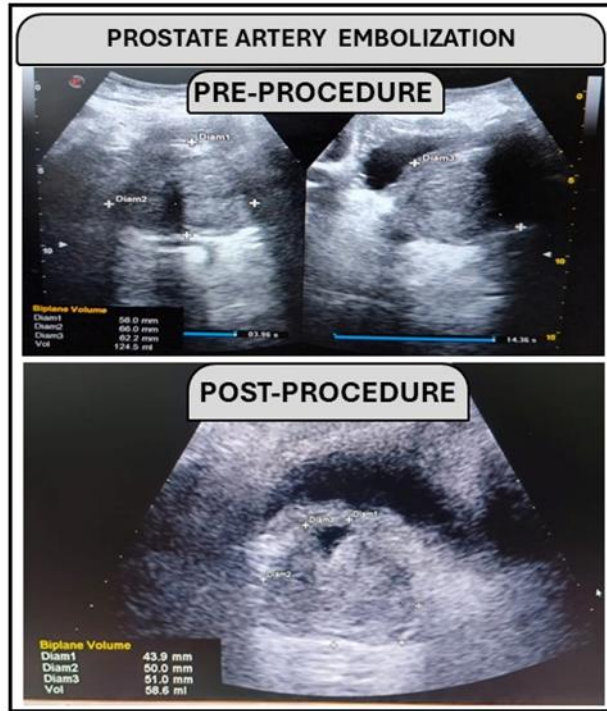
Citation: S. Zakir Hussain. Uterine artery embolization (UAE). *Kauverian Med J.* 2026;3(4):63–65.

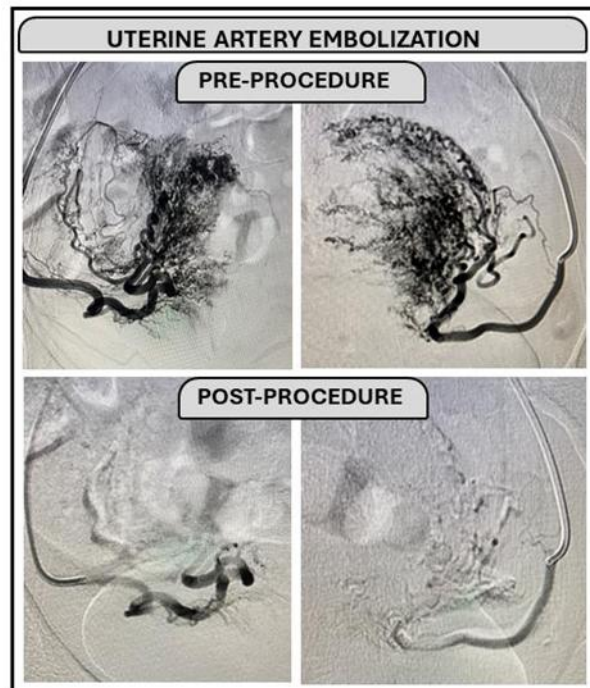
Academic Editor: Dr. Venkita S. Suresh

ISSN: 2584-1572 (Online)



Copyright: © 2026 by the authors. Submitted for possible open access publication under the terms and conditions.





2. Acknowledgement

We thank Dr. Suchitra , Dr. S.Senthil kumar and Dr. Sasi Kumar for their valuable support.