



Case Report

# The scorpion block: A sting operation

J. Sivagurunathan, S. Khaja Mohideen, K. Senthil Kumar\*

Department of Anaesthesiology, Kauvery Hospitals, Trichy, Tamilnadu, India

\* Correspondence

**Abstract:** Subarachnoid block is the preferred technique of anaesthesia for lower abdominal and lower limb surgeries. Resistance or failure to achieve the block with local anaesthetic agent by various routes is an uncommon but known phenomenon. Various factors have been attributed to this, one of them being scorpion venom. Here we report one such case of failed spinal anaesthesia in a patient with history of scorpion sting.

**Keywords:** Resistance to local anaesthesia; failed spinal anaesthesia; scorpion venom

## 1. Introduction

Subarachnoid block, commonly referred to as spinal anesthesia, is widely recognized as the preferred technique for a variety of surgical procedures involving the lower abdomen and lower limbs. This method has gained popularity due to its remarkable efficacy and favorable safety profile. Anesthesiologists often choose this approach for its ability to provide rapid onset of anesthesia, excellent muscle relaxation, and effective pain control during and after surgery. The technique involves injecting a local anesthetic into the subarachnoid space, which surrounds the spinal cord, resulting in a temporary block of nerve impulses.

However, despite its widespread use and generally high success rate, there are rare instances where resistance or failure to achieve the desired anesthetic effect can occur. These situations present significant challenges for anesthesiologists and can potentially compromise patient safety and surgical outcomes. While several factors can contribute to this phenomenon, including anatomical variations, technical difficulties, or drug-related issues, one intriguing and lesser-known cause has emerged in recent years: the presence of scorpion venom in the patient's system.

This unusual connection between scorpion stings and failed spinal anesthesia has been documented in medical literature, albeit infrequently. The case report in question highlights one such instance where a patient with a history of scorpion sting experienced a failed spinal anesthesia, shedding light on the potential long-term effects of scorpion envenomation on the nervous system and its interaction with local anesthetic agents. This unexpected relationship between scorpion venom and anesthetic resistance has sparked interest among researchers and clinicians alike, prompting further investigation into the underlying mechanisms.

Scorpion venom is a complex mixture of bioactive compounds, including neurotoxins, which can have profound effects on the nervous system. These toxins primarily target ion channels in nerve cells, disrupting normal neuronal function. While the acute effects of scorpion envenomation are well-documented and can be life-threatening, the long-term consequences on the nervous system are less understood. The case report suggests that these toxins may have lasting effects on the nervous system, potentially altering its response to local anesthetics used in spinal anesthesia.

**Citation:** Sivagurunathan J., Khaja Mohideen, Senthil Kumar, K. The scorpion block—A sting operation. *Kauverian Med J*, 2024;1(10):1-4.

Academic Editor: Dr. Venkita S. Suresh

ISSN: 2584-1572 (Online)



**Copyright:** © 2024 by the authors. Submitted for possible open access publication under the terms and conditions.

The implications of this finding are significant for anesthesiology practice. It underscores the importance of thorough patient history-taking, including seemingly unrelated events such as scorpion stings, which may have occurred months or even years prior to the surgical procedure. Anesthesiologists must be vigilant and consider such rare complications when encountering unexpected resistance to regional anesthesia techniques. This knowledge may prompt them to explore alternative anesthetic approaches or take additional precautions to ensure patient safety and comfort during surgery.

Furthermore, this case highlights the need for continued research into the long-term effects of scorpion envenomation on human physiology, particularly its impact on the nervous system and potential interactions with commonly used medications. Understanding these mechanisms could lead to the development of new strategies to overcome anesthetic resistance in affected patients or even novel treatments for neurological conditions.

In conclusion, while subarachnoid block remains a highly effective and widely used anesthetic technique, the reported case of failed spinal anesthesia due to previous scorpion envenomation serves as a reminder of the complex interplay between environmental factors, human physiology, and medical interventions. It emphasizes the importance of comprehensive patient assessment, awareness of rare complications, and the need for ongoing research in anesthesiology to ensure optimal patient care and safety in all surgical scenarios.

## 2. Case Presentation

A 13-year-old boy weighing 38 kg, was posted for wound debridement of right foot. He had no comorbid illness. His blood investigations were normal and hence assessed under ASA-PS IE for spinal anaesthesia. Under strict aseptic precautions with patient in sitting position, spinal anaesthesia was given at L3-L4 inter vertebral space using 27G Whitacre spinal needle in single attempt with 2.5 ml of 0.5% hyperbaric Bupivacaine. The drug (2.5 ml of 0.5% hyperbaric bupivacaine) was injected into sub arachnoid space after confirming free flow of CSF on aspiration. The patient was then made to lie supine. Even after waiting for 20 min patient did not develop sensory or motor block. His haemodynamics were also stable. The spinal drug and its shelf life was once again verified and was found to be appropriate. Once again spinal anaesthesia was repeated with 2ml of 0.5% hyperbaric Bupivacaine using the same size needle at L2-L3 inter vertebral space. In spite of waiting for nearly 30 min, patient did not develop sensory or motor block. On enquiring the patient once again, he remembered and gave history of scorpion sting 8-10 months back. Resistance to local anaesthetic action was considered. Hence the procedure was carried out under general anaesthesia. The surgical duration was about 90 minutes and uneventful. Patient did not develop any sensory or motor blockade in the postoperative period also.

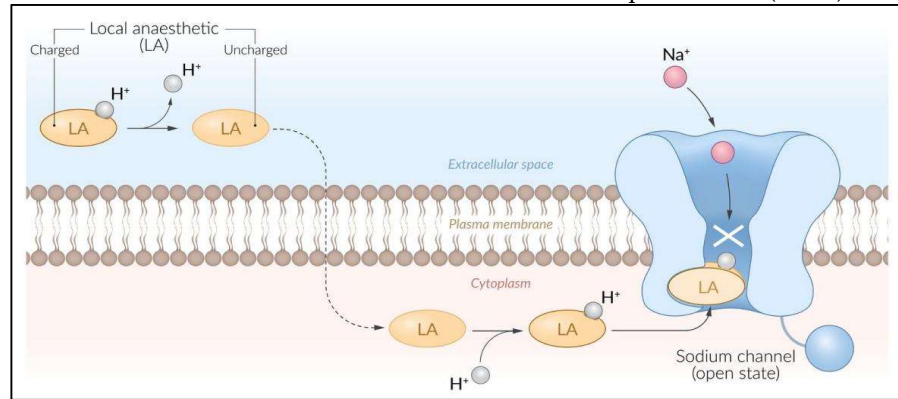
## 3. Discussion

Spinal anaesthesia is a blind procedure that is performed by identifying the anatomical landmarks. Causes of failed spinal anaesthesia are

- 1) Successfully injected drugs that are mal-distributed relative to the needs of the planned surgery.
- 2) Unrecognized failed injection of drugs.
- 3) Technical failure to enter the subarachnoid space with no drug injection.
- 4) Drug errors i.e., expired drugs and in-appropriate additives.
- 5) Local anaesthetic resistance.
- 6) Pseudo block failure due to excessive expectations for speed of block onset.
- 7) Subdural injection of drug.

Local anaesthetic agents act by binding with sodium channel in closed, open or inactivated state. Sodium channel have three subunits eg; alpha, beta-1 and beta-2 subunits.

The alpha subunit has further four homologous domains (I-IV) and each domain is made up of six Trans membrane segments (S1-S6). Mechanism of action of local anaesthetics is believed to be due to interaction with S6 of domain four of alpha subunit (IV-S6).

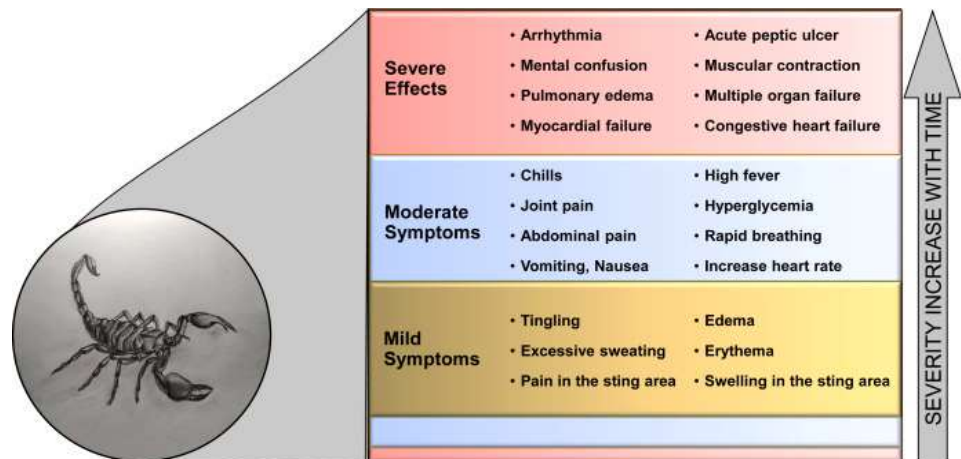


*Hottentotta tamulus*- the Indian red scorpion, belongs to the family Buthidae, and is commonly found in India. Scorpions use their venom to defend against predators and to capture prey.



The composition of scorpion venom is highly complex and heterogeneous. Up until now, small scorpion venom peptides are the most studied compounds mainly due to their diversity and broad pharmacological properties. Accordingly, to their structure, these small peptides are classified into three large super families: peptides containing cysteine-stabilized (CS)  $\alpha/\beta$  motifs, calcins, and non-disulfide bridged peptides (NDBPs). However, enzymes (larger proteins), mixtures of inorganic salts, free amino acids, nucleotides, amines, and lipids are also found in scorpion venom.

The venom of some species can cause prolonged depolarization by causing incomplete inactivation of sodium channels resulting in a slow influx of sodium. This influx then leads to membrane hyper excitability and unregulated axon firing by inhibiting the inactivation of an action potential. The neurotoxins also cause the excessive release of acetylcholine from parasympathetic ganglia as well as the release of epinephrine and norepinephrine from sympathetic ganglia and the adrenal glands. In turn, envenomation can produce cholinergic as well as sympathetic stimulation. Typical cholinergic symptoms include diaphoresis, priapism, lacrimation, vomiting, diarrhea, and bradycardia. Typical sympathetic symptoms include hypertension, tachycardia, and restlessness.



Alpha and Beta toxins act on sodium channels. Scyllatoxin, charybdotoxin and tityus toxin inhibits calcium dependent potassium channels and also causes opening of sodium channels at presynaptic nerve terminals.

Scorpion venom and local anaesthetic agents have common site of binding i.e., the S6 of domain four of alpha subunit (IV-S6). The proposed hypothesis for this local anaesthetic resistance is the elicitation of strong immunological response by the antigenicity of scorpion venom. This leads to the development of antibodies against the binding site. As the binding site is same for local anaesthetic, later on in life when these sensitized persons are exposed to local anaesthetic agents, the drugs are unable to bind with the receptor because of the competitive antagonism by the antibodies formed.

The resistance may manifest as inadequate block or block failure requiring conversion to general anaesthesia. Studies show that, in patient with recent history of scorpion sting (<6 months) there is complete failure of spinal anaesthesia. Whereas in patients with history of scorpion bite > 6months and >1 year had delayed onset of sensory or motor block and adequate level of blockade respectively.

#### 4. Conclusions

Previous single/multiple scorpion sting can cause development of resistance to the effect of local anaesthetic agents administered via various routes. Number of sting and more recent the sting, more the chances of failure or inadequate block or delayed onset of action. Hence attention should be paid in eliciting previous history of scorpion sting and duration since last sting. Regional anaesthesia should be avoided in patients with recent (6–8 months) history of scorpion sting.

#### References

1. Panditrao MM, Panditrao MM, Panditrao AM. Development of resistance to the effect of local anesthetic agents administered via various routes due to single or multiple, previous scorpion bites: a proposed hypothesis and reporting a yet unrecognized phenomenon. *J Anesth Crit Care Open Access*. 2015;3(5):00110.
2. Panditrao MM, Panditrao MM, Sunilkumar V, Panditrao AM. Effect of previous scorpion bite (s) on the action of intrathecal bupivacaine: A case control study. *Indian journal of anaesthesia*. 2013 May 1;57(3):236-40.
3. Kosam D, Nigam R, Murthy M, Debbarma M, Chatterjee S. Effect of previous scorpion sting on the efficacy of spinal anaesthesia—a case control study. *Int J Med Res Rev*. 2015;3(8):826-31.
4. Ahmadi S, Knerr JM, Argemi L, Bordon KC, Pucca MB, Cerni FA, Arantes EC, Çalışkan F, Laustsen AH. Scorpion venom: detriments and benefits. *Biomedicines*. 2020 May 12;8(5):118.
5. Shamooun Z, Peterfy RJ, Hammoud S, et al. Scorpion Toxicity. [Updated 2023 Aug 8]. In: StatPearls [Internet]. Treasure Island (FL): StatPearls Publishing; 2024 Jan.