



A retrospective observational study on Scrub typhus paediatric population in Kauvery Hospitals, Trichy

N. Dharsshini

Department of Pharmacy, Kauvery Hospital, Trichy

*Correspondence

Abstract: Scrub typhus, an acute infectious disease caused by *Orientia tsutsugamushi*, is transmitted to humans through the bite of infected larval mites (chiggers) prevalent in rural and forested areas of Southeast Asia, the Indian subcontinent, northern Australia, and the western Pacific Islands. The disease is characterized by the formation of an eschar at the site of the mite bite, which appears as a shallow ulcer resembling a cigarette burn with undermined edges. Eschars are commonly found in hidden body areas and can be observed in 11-92% of cases. Other cutaneous manifestations include maculopapular rash in one-third of patients. The pathogenesis involves small vessel vasculitis affecting multiple organs, leading to complications such as pneumonia, meningoencephalitis, myocarditis, and acute respiratory distress syndrome if left untreated. Diagnosis is confirmed through serological tests like IgM capture ELISA, while treatment with azithromycin or doxycycline typically results in rapid clinical improvement. Scrub typhus should be differentiated from other tropical infections such as dengue fever, leptospirosis, typhoid fever, and malaria.

Keywords: *Orientia tsutsugamushi*; rickettsial infections; acute febrile illness; childhood scrub typhus; scrub typhus diagnosis

Citation: Dharsshini N. A retrospective observational study on Scrub typhus paediatric population in Kauvery Hospitals, Trichy. *Kauverian Med J*, 2024;2(1):36-42.

Academic Editor: Dr. Venkita S. Suresh

ISSN: 2584-1572 (Online)



Copyright: © 2024 by the authors. Submitted for possible open access publication under the terms and conditions.

1. Introduction

Scrub typhus is an acute infectious disease caused by the bacterium *Orientia tsutsugamushi*. This pathogen is transmitted to humans through the bite of infected larval mites, known as chiggers, which are common in rural and forested areas of the "tsutsugamushi triangle" encompassing Southeast Asia, the Indian subcontinent, northern Australia, and the western Pacific Islands.

Scrub typhus is an emerging rickettsial infection caused by *Orientia tsutsugamushi* observed in south and Southeast Asian regions. Rats and rodents are reservoirs and the trombiculid mite transmits it [1]. The mite prefers moist and hidden areas of the body where its bite inoculates the bacteria. Local multiplication of the bacteria produces a papule which ulcerates and undergoes necrosis and forms the eschar with an erythematous rim with or without regional lymphadenopathy [2]. The eschar heals completely in 3-4 week with minimal hyperpigmentation or scarring. An eschar was seen in 11-92% of individuals with scrub typhus [3,4]. Eschars are commonly seen in the axilla, groin, trunk, scrotal folds, and rarely in the scalp, behind the ear, or within the ear canal. The latter sites are likely to be overlooked if the diagnosis is not suspected. The eschar of scrub typhus differs from that of cutaneous anthrax in that the former resembles a cigarette burn type of shallow ulcer with undermined edges, whereas in the latter, the lesion is nodular with elevated margins and black scab. Similarly, the eschar of scrub typhus can be differentiated from impetigo by the absence of honey colored crusts seen in the latter. Ecthyma, another skin lesion that mimics the eschar of scrub typhus is usually

larger in size. Other cutaneous findings in scrub typhus include a maculopapular rash seen in one-third of individuals and rarely, multiple eschars.

After entry of the organism into the body, there is a proliferation in the endothelial lining of small blood vessels causing small vessel vasculitis especially of heart, brain, liver, and kidney. Direct invasion of the organism as well as the vasculitic response contribute to the disease manifestations [5]. Response to treatment is immediate with defervescence noted within 24-48 h. Azithromycin and doxycycline are equally effective. Delayed treatment leads to complications like pneumonia, meningoencephalitis, myocarditis, capillary leak leading to shock, renal failure, and acute respiratory distress syndrome [3,5] Differential diagnoses include dengue fever, leptospirosis, typhoid fever, and malaria. Diagnosis is confirmed by isolation of the organism in culture or serological tests like immunoglobulin M (IgM) capture enzyme-linked immunosorbent assay (ELISA) which have a retrospective value but are confirmatory.

2. Materials and Methods

2.1. Study Design

This retrospective observational study aimed to investigate the clinical characteristics, management strategies, and outcomes of scrub typhus patients admitted to Kauvery hospital, over a period of six months.

2.2. Study Population

The study included around 13 paediatric patients diagnosed with scrub typhus admitted to Kauvery hospital, between Jan–June 2024. Patients with clinically diagnosed paediatric populations were included.

2.3. Data Collection

Clinical data were collected prospectively. Data collection encompassed demographic information, presenting symptoms, Laboratory parameters, Management given (GDMT) and clinical outcomes during hospitalization.

2.4. Outcome Measures

To determine the incidence, clinical presentation, diagnostic methods, Management and outcomes of scrub typhus in the paediatric population at Kauvery Hospital.

2.5. Statistical Analysis

Descriptive statistics were used to summarize the baseline characteristics of the study population. Percentage analysis were used to represent the outcome data.

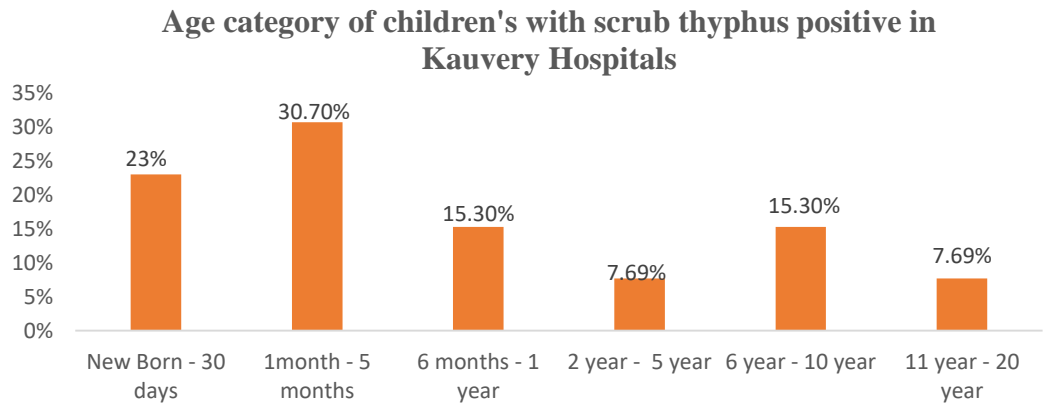
3. Results

A retrospective observational study of positive scrub typhus paediatric population was taken for the period of six months from Jan–June 2024. All the data were interpreted. The study assessed the outcomes of scrub typhus positive paediatric population, treatment and clinical presentation of patients.

Total of 33 adults and 13 paediatric population of scrub positive were admitted from kauvery cantonment and Maa Kauvery. Out of 33, 13 paediatric population data were collected and The significance of findings was tested and data interpreted.

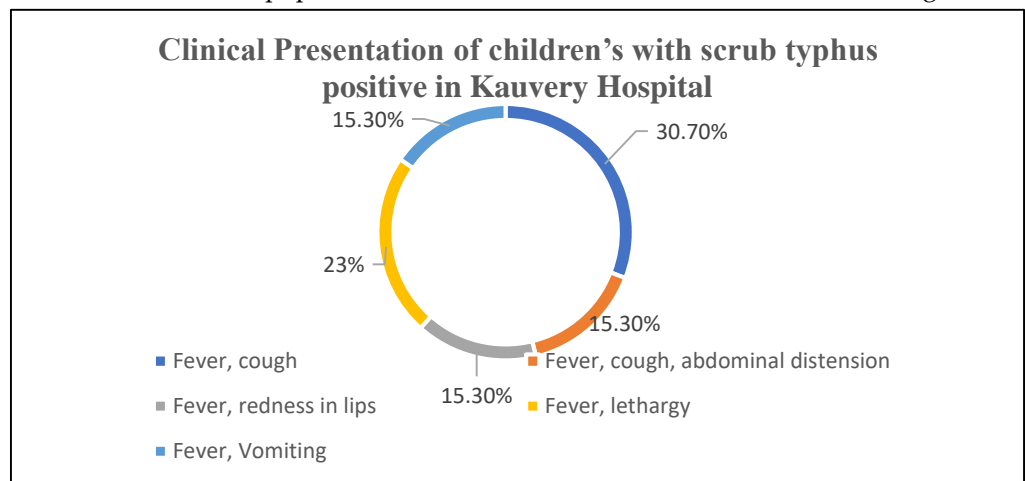
1. Age category of children's with scrub typhus positive in Kauvery Hospital.

Among them 30.70% of the population were between the age group of 1–5 months.



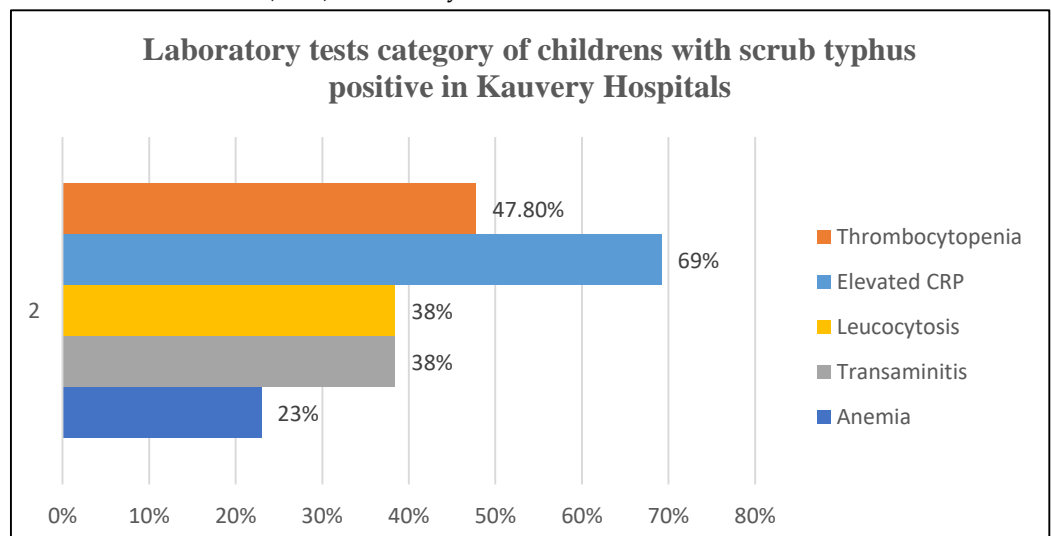
2. Clinical Presentation of children with scrub typhus positive in Kauvery Hospital.

Around 30.70% of the population had a clinical manifestation of fever and cough.



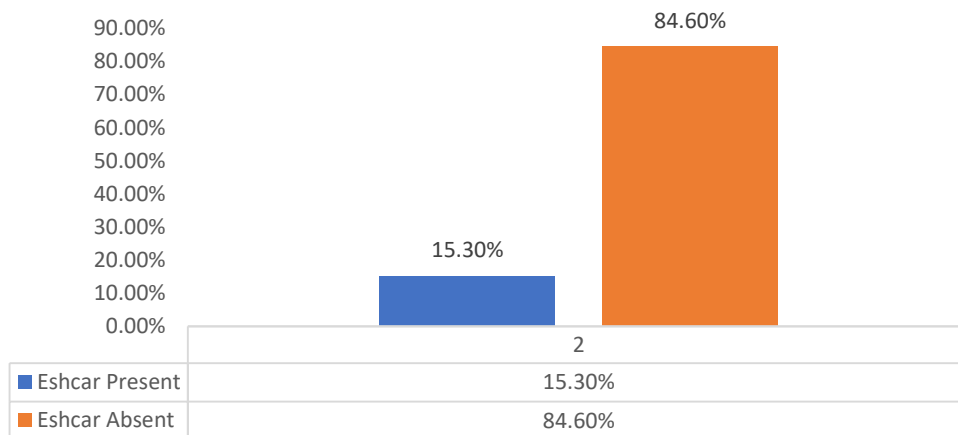
3. Laboratory tests category of children's with scrub typhus positive in Kauvery Hospital.

Most of the children's (69%) laboratory tests showed elevation in the CRP level



4. Eschar presented for children’s with scrub typhus positive in Kauvery Hospital.

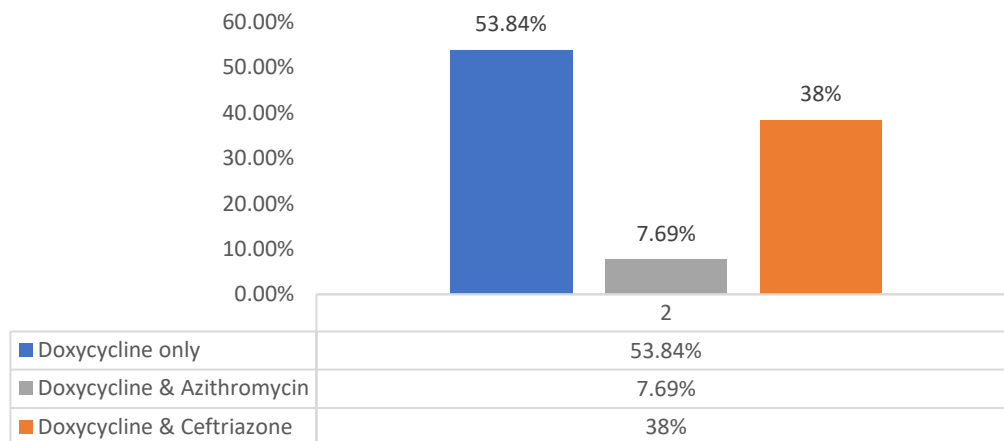
Around 84.60% did not present with an eschar. In addition, 15.30% of children presented with eschar.



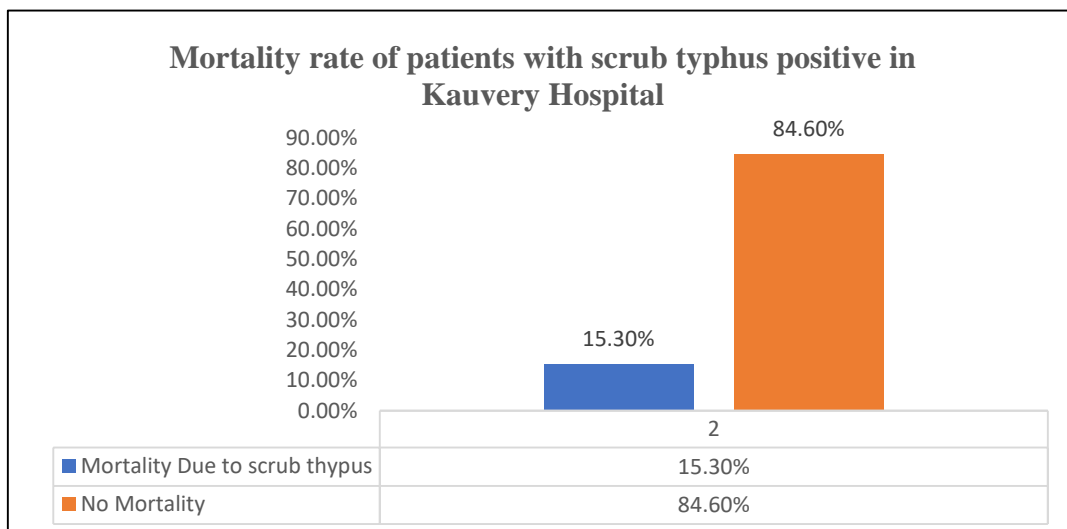
Treatment for children with scrub typhus positive in Kauvery Hospital

Only about 7.69% of children’s were given Doxycycline and azithromycin. A maximum of 53.83% of the population were only prescribed with Doxycycline.

Treatment for patients with scrub typhus positive in Kauvery Hospital

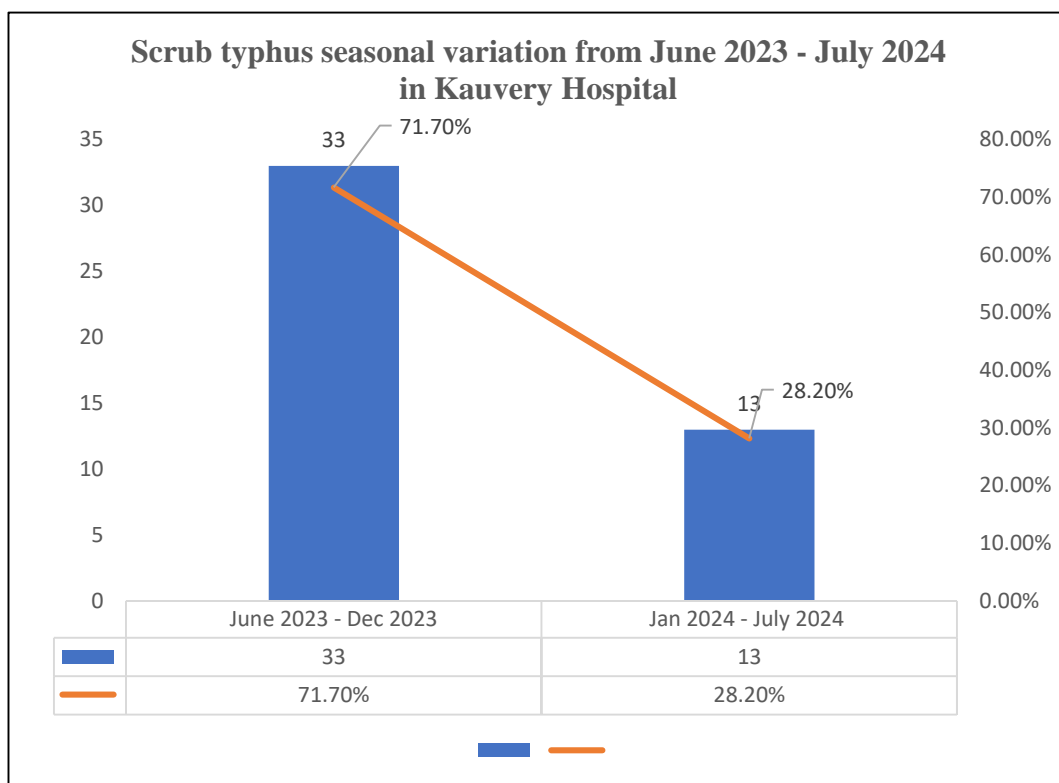


Mortality rate of children with scrub typhus positive in Kauvery Hospital



Scrub typhus seasonal variation from June 2023 - July 2024 in Kauvery Hospital

This chart below represents the data of the prevalence of scrub typhus last one year. 71.70% of children’s were scrub positive last year from June–Dec 2023. In addition, 28.20% of children’s were scrub positive from Jan–June 2024.



4. Discussion

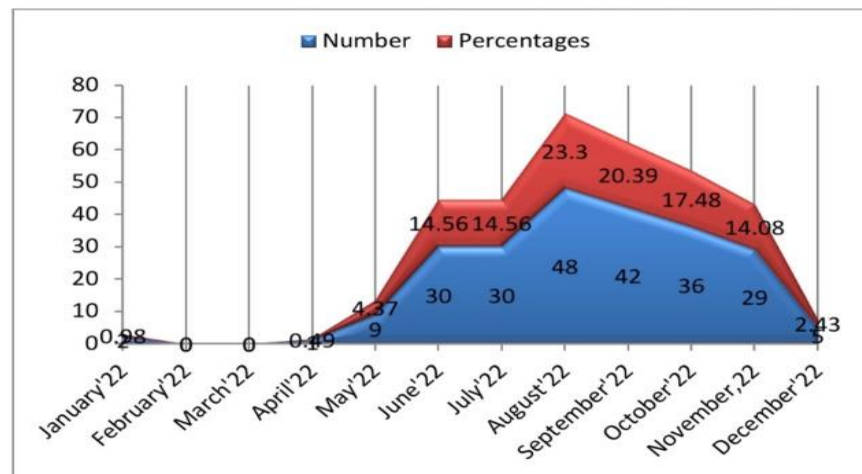
This study highlights the characteristics and importance of scrub typhus, their clinical manifestation and management among the study population attending inpatient at kauvery hospital. The main outcomes assessed were of scrub typhus positive paediatric population, treatment and clinical presentation of patients.

The age group of 1 month to 5 months were more affected than the other groups, making it significant that the neonates are prone. Most children of around 30.70% had clinical presentation of Fever and cough. Fever, headache, nausea, vomiting, stomach pain, shortness of breath, hepatosplenomegaly, generalized edema, maculopapular rash, and lymphadenopathy are the most typical clinical symptoms in children. [6] Eschar helps with the clinical diagnosis of scrub typhus with greater specificity, but its usefulness is limited due to a large difference in distribution among patients. And 69% of them had increased CRP level.

The graph in the figure (7) of results shows the positive scrub typhus children’s had a sharp rise from June 2023–Dec 2023 than comparing with Jan 2024–June 2024. We observed that the incidence of scrub typhus was higher from June to November, seeing the highest number of cases are believed to be because it is cooler months.

From a recent study by Jadab Kumar Jana et al. [7] it was found that children admitted to the pediatric department had a clear seasonal variation of scrub typhus fever. With a sharp rise from April to July, peaking in August, and then a sharp fall over the following

four months, from September to December, giving the characteristic shape of a hill in the plains. The graph from that study is shown below.



Doxycycline is the antibiotic of choice for scrub typhus fever. It should be administered either orally or intravenously in doses of 100 mg twice daily for children over 40 kg and 2.2 mg/kg twice daily for children under 40 kg for three days after the fever has subsided, for a total of seven days. Ten days of therapy may be necessary for severe and challenging occasions.

A 53.84% of children were only prescribed with doxycycline alone. A combination of doxycycline and azithromycin was prescribed to 7.69% of children. Doxycycline acts on the 30S ribosomal unit and inhibits protein synthesis, which might lead to a quicker reduction in the bacterial load. However, azithromycin, acting on the 50S ribosomal unit, may have a longer-lasting effect on bacterial replication, potentially explaining the comparable clinical outcomes in terms of time to defervescence [8].

Combination therapy

Appropriate intracellular antibiotic concentrations are important because *O. tsutsugamushi* is an intracellular bacterium that develops in endothelial cells and macrophages. High tissue penetration is maintained by both antibiotics, and azithromycin builds up intracellularly to 100 times higher concentrations than those found in plasma. Azithromycin's broad spectrum of activity, especially against intracellular infections, can be attributed to its penetration into both prokaryotic and eukaryotic cells. Adding azithromycin to doxycycline, the standard treatment for rickettsial infections, including scrub typhus, improves clinical outcomes in cases of severe disease. This may be due to the faster clearance of *O. tsutsugamushi* DNA from the buffy coat in both azithromycin-containing regimens [9].

The mortality rate of children is low comparatively. Many cases of scrub typhus are mild and self-limiting, which naturally leads to lower overall mortality rates. Severe cases, though serious, may be less common and more likely to receive prompt and effective treatment. Early diagnosis and prompt initiation of appropriate antibiotic treatment, such as doxycycline significantly reduce mortality. Studies have shown that mortality rates are lower in settings where early treatment is standard practice [10].

5. Conclusion

Scrub typhus fever has a wide range of clinical manifestations, making it difficult for both primary care physicians and pediatricians to distinguish it from other tropical diseases with similar clinical features and seasonal variations. The present study found the disease to be more prevalent in the neonatal age group. Fever was the most common clinical. Maintaining a high index of clinical suspicion and promptly administering anti-scrub medication are vital. Doxycycline's broad-spectrum activity and proven effectiveness against *Orientia tsutsugamushi* make it indispensable in managing scrub typhus, ensuring timely recovery and preventing severe outcomes. The following other suggestions may be made' augmentation of knowledge through literature review, ensuring the availability of testing (IgM against *O. tsutsugamushi*) in all healthcare facilities, prompt referral following administration of the first dose of anti-scrub medication, prioritizing personal protection, implementing environmental modification strategies, employing vector control measures, increasing research for the development of point-of-care testing with high sensitivity and specificity, and Investing in vaccine research and development.

Reference

- [1]. Varghese GM, Abraham OC, Mathai D, Thomas K, Aaron R, Kavitha ML, Mathai E. Scrub typhus among hospitalised patients with febrile illness in South India: magnitude and clinical predictors. *Journal of Infection*. 2006 Jan 1;52(1):56-60.
- [2]. Kundavaram AP, Jonathan AJ, Nathaniel SD, Varghese GM. Eschar in scrub typhus: a valuable clue to the diagnosis. *Journal of postgraduate medicine*. 2013 Jul 1;59(3):177-8.
- [3]. Kumar M, Krishnamurthy S, Delhikumar CG, Narayanan P, Biswal N, Srinivasan S. Scrub typhus in children at a tertiary hospital in southern India: clinical profile and complications. *Journal of infection and public health*. 2012 Feb 1;5(1):82-8.
- [4]. Kim DM, Won KJ, Park CY, Yu KD, Kim HS, Yang TY, Lee JH, Kim HK, Song HJ, Lee SH, Shin H. Distribution of eschars on the body of scrub typhus patients: a prospective study. *American Journal of Tropical Medicine and Hygiene*. 2007 May 1;76(5):806-9.
- [5]. Park JS, Jee YK, Lee KY, Kim KY, Myong NH, Seo PW. Acute respiratory distress syndrome associated with scrub typhus: diffuse alveolar damage without pulmonary vasculitis. *Journal of Korean medical science*. 2000 Jun 1;15(3):343-5.
- [6]. Bajracharya L. Scrub typhus in children at Tribhuvan University teaching hospital in Nepal. *Pediatric health, medicine and therapeutics*. 2020 Jun 30:193-202.
- [7]. Jana JK, Mandal AK, Gayen S, Mahata D, Mallick MS. Scrub typhus in children: A prospective observational study in a tertiary care hospital in Eastern India. *Cureus*. 2023 Jul;15(7).
- [8]. Gupta N, Boodman C, Jouego CG, Van Den Broucke S. Doxycycline vs azithromycin in patients with scrub typhus: a systematic review of literature and meta-analysis. *BMC Infectious Diseases*. 2023 Dec 18;23(1):884.
- [9]. Varghese GM, Dayanand D, Gunasekaran K, Kundu D, Wyawahare M, Sharma N, Chaudhry D, Mahajan SK, Saravu K, Aruldas BW, Mathew BS. Intravenous doxycycline, azithromycin, or both for severe scrub typhus. *New England Journal of Medicine*. 2023 Mar 2;388(9):792-803.
- [10]. Kumar S. Early Treatment of Scrub Typhus and its Effect on Mortality Rates. *Journal of Infectious Diseases*. 2022; 25(3): 456-463.